Dynamic Contrast Enhanced Magnetic Resonance Imaging Detects Interatrial Shunts in Patients with Patent Foramen Ovale and Atrial Septal Defect Before and After Percutaneous Defect Closure

S. Bohl[1], R. H. Strasser[1], T Kittner[2], M. U. Braun[1], S. P. Schoen[1]

[1] University of Dresden, Department of Cardiology

[2] University of Dresden, Department of Radiology

Corresponding Author

Dr. med. S. P. Schoen

University of Dresden, Department of Cardiology, Heart Center

Fetscherstr. 74

01309 Dresden, Germany

Dynamic Contrast Enhanced Magnetic Resonance Imaging Detects Interatrial Shunts in Patients with Patent Foramen Ovale and Atrial Septal Defect Before and After Percutaneous Defect Closure

Introduction: Interatrial communications (IC) are the most frequent lesions in congenital heart disease (CHD). The patent foramen ovale (PFO) is a common but rarely symptomatic finding: a prevalence of up to 35% is reported[1]. Secundum type atrial septal defect (ASD) accounts for 7-10% of all congenital heart malformations[2,3]. Both types of IC can remain clinically silent for decades or even a lifetime, but a considerable number of patients will turn symptomatic with paradoxical embolism (PFO and ASD) or progressive right heart failure (ASD)[4-6]. Patients with a wide opening of the PFO permitting a large right-to-left-shunt or a PFO associated with atrial septal aneurysm (ASA) are at an increased risk of potentially deleterious paradoxical thromboembolism[7]. In the case of ASD long-term exposure to chronic right heart volume overload leads to dilatation of the right atrium (RA) and ventricle (RV) and in certain cases, due to an increased pulmonary flow, to deleterious effects such as pulmonary hypertension and right heart failure <RV2>. Patients may present symptoms of fatigue, dyspnea, recurrent lower respiratory tract infection, palpitations and thromboembolic events[8]. Modern treatment strategies have established percutaneous closure of interatrial defects with various types of closure devices as a promising alternative to surgical procedures (PFO and ASD) or long-term medical treatment (antiaggregatory drugs or oral anticoagulation for prevention of PFO-associated thromboembolic events)[9-12]. These percutaneous techniques have been shown to be safe and efficient[13, 14]. While optimal treatment of PFO is still controversially discussed[15, 16], it has been accepted that closure of an ASD is the treatment of choice in patients with significant pulmonary to systemic flow ratio, especially if RV volume overload is present, even if the patient has few or no symptoms [17, 18]. Up to the present transesophageal echocardiography (TEE) serves as the most important diagnostic tool in the evaluation of IC[19]. This procedure, though, is semiinvasive and comprises a complication rate of approximately 1%[20]. Magnetic Resonance Imaging (MRI) has been shown to be a powerful tool in the assessment of CHD[21].

The Aim of this study was to prospectively assess the diagnostic performance of contrast enhanced MRI in the initial diagnosis of PFO and ASD as well as during the follow-up period after percutaneous closure of both PFO and ASD.

PATIENTS AND METHODS

Patient population: We prospectively studied 20 consecutive patients with IC (14 patients with PFO, mean age 43 ± 16 years, 8 males; 6 patients with ASD II, mean age 35 ± 14 years, 2 males) with TEE and MRI at baseline and 6 months after percutaneous defect closure with a Cardia PFO / ASD

occluder (Cardia Inc.). All patients with PFO had a history of paradoxical embolism. An independent neurologist confirmed the diagnosis "cryptogenic cerebral ischemia" after all other identifiable causes of ischemic stroke had been ruled out (1. cardiogenic embolism; 2. hypercoagulable state by laboratory testing for thrombophilia: factor V Leiden mutation, prothrombin 20210 mutation, antiphospholipid antibodies, protein C deficiency, protein S deficiency, antithrombin III deficiency; 3. atherothrombotic events; 4. vasculitis; 5. autoimmune disease).

Table 1 shows clinical characteristics/cardiovascular risk factors of the included patients with PFO.

Table 1

Cryptogenic stroke	6 (43%)
Crytprogenic TIA	7 (50%)
Peripheral embolism	1 (7%)
ASA	5 (35%)
spontaneous right to left shunt	11 (78%)
arterial Hypertension	5 (35%)
Hyperlipoproteinemia	3 (21%)
Nicotine-abuse	1 (0,7%)
Migraine	1 (0,7%)

2 patients with ASD displayed only minute left-to-right shunt but were symptomatic with paradoxical embolism. The remaining 4 patients with ASD presented with dyspnea on exertion and showed echocardiographic signs of right heart failure.

Table 2 shows clinical characteristics of the included patients with ASD:

Table 2

Qp:Qs > 1.5:1	4 (66%)
Mean stretched defect diameter (mm)	19 ± 4
Paradoxical embolism	2 (33%)

Additionally, 7 individuals without an IC on TEE underwent the identical MRI protocol and served as controls. The presence/absence of transatrial shunt was defined as the primary variable. Contrast-enhanced TEE was defined as the goldstandard and compared to a dynamic contrast-enhanced MRI protocol. Before undergoing MRI, all patients gave written informed consent in accordance with ethical guidelines followed in our institution.

Transesophageal echocardiography

2-dimensional color Doppler TEE was performed before and six months after ASD closure, using a Sonos 5500 ultrasound system (Agilent Technologies) with a 5MHz phased multiplane probe. D-Galactose was used as intravenous contrast agent (Echovist©, Schering AG) and administered as 10ml bolus into an antecubital vein. A Valsalva maneuver (VM) was performed by the patient at the physician`s disposition for 5 seconds starting 5 seconds after contrast injection according to previously published protocols[22]. The transseptal appearance of contrast bubbles in the left atrium (LA) within 3 heartbeats after appearance in the right atrium (RA) was considered a right-to-left shunt. The examination focussed on the IAS and was performed in the mid-esophageal position at rest and under VM. The presence of ASA was defined as a dynamic bulge of the IAS into LA or RA of >10mm.

Magnetic Resonance Imaging: MRI was performed on a clinical 1,5 T MRI system (Vision Magnetom, Siemens Medical Solutions, Erlangen, Germany) with a dedicated phased-array cardiac coil. ECG-gated cine cineGradient Echo (cineGE; parameters) were used to detect the IAS-region in long-axis orientation. The IAS was studied in the 4-chamber view (4CV) with ECG-gated turbo Spin Echo (tSE, parameters:) and cineGE. Septal thinning or focal discontinuity within the central portion/fossa ovalis was assessed. In both TSE and cineGE the suspected defect-diameter was measured in 2 planes at the maximum gap.

When adequate visualisation of the central portion of the IAS was achieved patients were asked to

perform successive VM under breathhold conditions. Patients were asked to perform each VM identically with respect to the considerable intrathoracal shift of the heart during VM. All patients had been exercising in performing the VM correctly. When an optimal imaging plane was accomplished dynamic contrast-enhanced Magnetic Resonance Perfusion (MRPI; parameters) was performed under VM. VM was performed for 5 seconds 5 seconds after automated intravenous bolus administration of 0,2mmol/kg Gadolinium-dTPA paramagnetic, T1-shortening contrast agent (Magnevist©, Schering AG, Berlin, Germany). In patients with PFO the transseptal arrival of contrast agent in the LA under VM was assessed visually in the MRPI. Diagnosis was confirmed by measurement of time dependent blood-pool signal intensity (SI) in defined regions-of-interest (ROI) in the RA, pulmonary veins (PV) and paraseptal LA. Transatrial right-to-left shunt was diagnosed when SI in LA was augmented before an increase in the PV was to be seen.

Figure 1

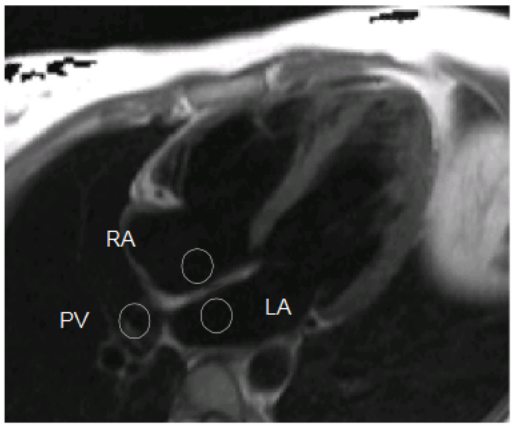

Figure 1 shows the regions-of-interest used for signal-time curve analysis

4 chamber viev, ECG-gated tSE, PV indicates pulmonary veins; RA, right atrium; LA left atrium

Implantation procedure

Percutaneous defect closure was performed under sedation and local anesthesia. The Cardia PFO / ASD Device (Cardia Inc.) was used for closure as previously described < Braun M, Gliech V, Boscheri A, Schoen S, Gahn G, Reichmann H, Haass M, Schraeder R, Strasser RH. Transcatheter closure of patent foramen ovale (PFO) in patients with paradoxical embolism. Periprocedural safety and mid-term follow-up results of three different device occluder systems. Eur Heart J. 2004 Mar;25(5):424-30 **und** Schoen SP, Kittner T, Bohl S, Braun MU, Simonis G, Schmeisser A, Strasser RH. Transcatheter closure of atrial septal defects improves right ventricular volume, mass, function, pulmonary pressure

and functional class: A MRI study. Heart. 2005 Nov 11; [Epub ahead of print]>. Postinterventional treatment included oral aspirin (100 mg/day) for 12 months, clopidogrel (75 mg/day) for 6 weeks and low dose heparin for the first 3 days (2 5000 IE s.c.) after intervention.

Statistics: Values are expressed as mean standard deviation.

Results:

On TEE 11 out of 14 patients with PFO showed spontaneous right-to-left shunt, 3 had right-to-left shunt under provocation by VM only, 5 patients with PFO displayed an associated ASA. All patients with ASD featured a left-to-right shunt on TEE, mean Qp/Qs was 1.7 0.2, mean stretched defect size was 19 4mm. Percutaneous defect closure was successful in all patients with PFO (mean device size 24 4mm) and ASD (mean device size 22 4mm). At 6 months 2 patients with primordial PFO were lost to follow-up. No adverse events had occurred in the remaining 18 patients. At 6 months TEE revealed a minimal residual transatrial shunt in 4 out of 18 patients (spontaneous left-to-right shunt in 2 patients with ASD and provoked right-to-left shunt in 2 patients with PFO).

Visual Assessment of Interatrial Communications with MRI:

tSE, cineGE and MRPI were performed to visualise IC. Compared to TEE as goldstandard for interatrial shunt detection results for each technique were the following:

On tSE the size of ASDs was systematically overestimated and yielded false-positive results in 16 out of 21 patients without ASD (14 patients with PFO and 7 patients without IC on TEE). As expected no clear depiction of PFO could be achieved with this imaging technique.

Using cineGE the size of ASDs was in good accordance to TEE-findings (Person`s correlation coefficient r=0.79; see figure 2). However correct diagnosis of PFO could also not be achieved by cine GE.

Figure 2

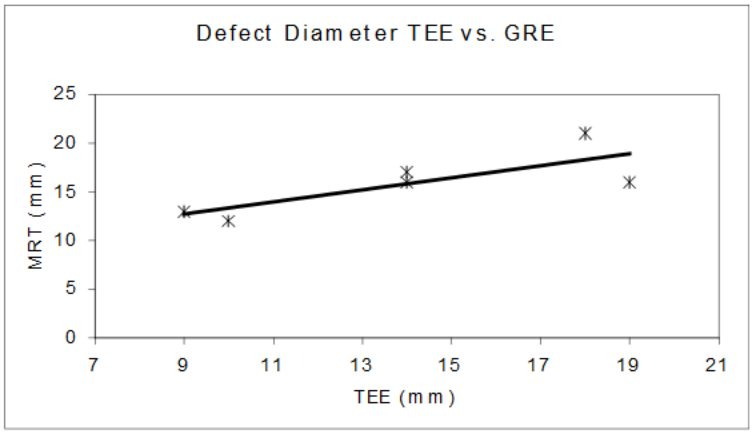

(Grafik hübscher) Figure 2 shows good correlation of ASD diameters as determined by transesophageal echocardiography versus MRI in cine Gradient Echo technique.

Using MRPI 11 out of 14 patients with PFO were diagnosed correctly. There were no false-positive results in the control group without IC (7 patients). Thus, a sensitivity of 0,78 and specificity of 1.0 for the detection of PFO resulted. Figure xy shows a representative MRPI of a patient with PFO and premature arrival of contrast agent in LA due to transseptal shunting under VM.

Dynamic Contrast Enhanced Magnetic Resonance Imaging Detects Interatrial Shunts in Patients with Patent Foramen Ovale and Atrial Septal Defect Before and After Percutaneous Defect Closure

Figure XY

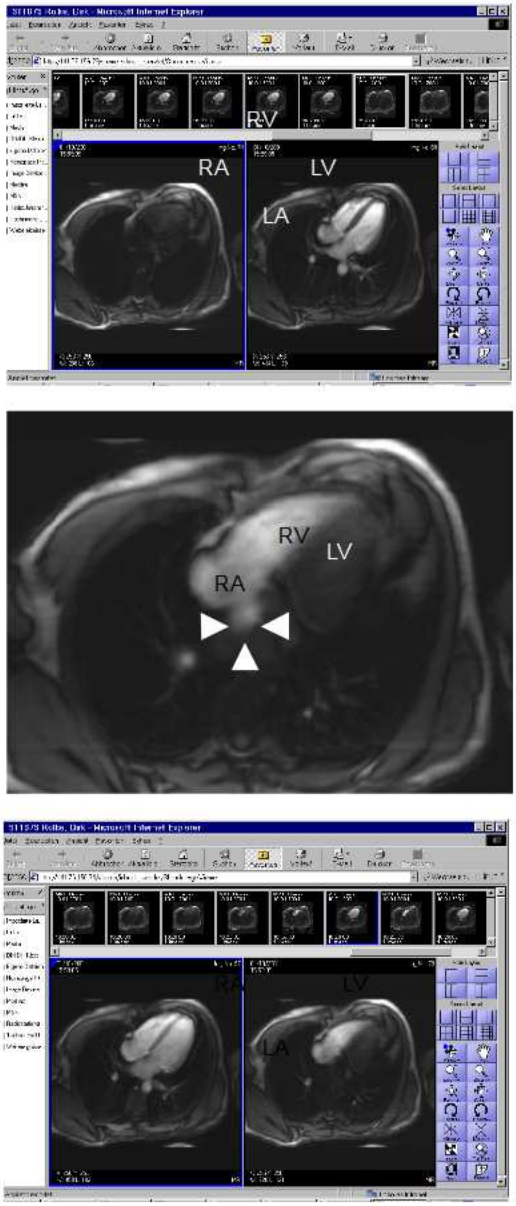

Auf Bildern A / B / C eintragen

a) baseline – no intracardiac contrast agent b) filling of the right heart with contrast and transseptal right-to-left shunting (arrowheads) c) situs after pulomary recirculation of the contrast agent with complete filling of all 4 chambers (RA indicates right atrium; RV, right ventricle; LA, left atrium; LV, left ventricle)

Visual analysis was confirmed by measurement of blood-pool SI in defined ROIs. Figure XY shows representative graphs derived from SI-time analysis in a patient without (**a**) and a patient with (**b**)

interatrial communication on TEE

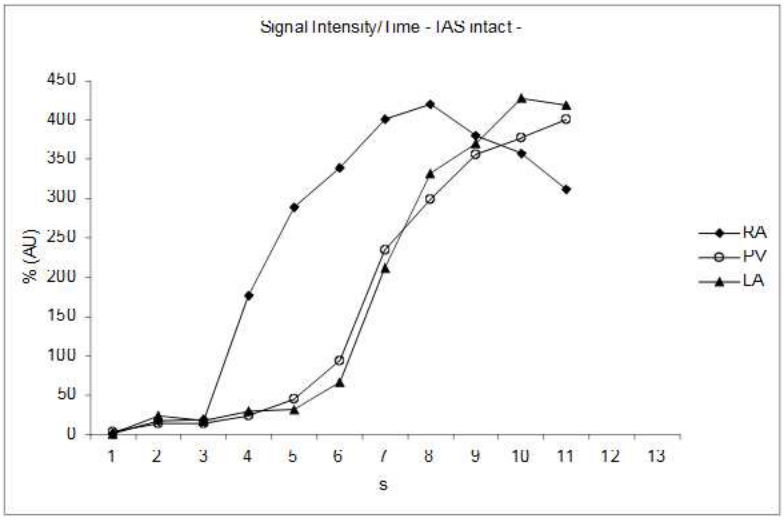

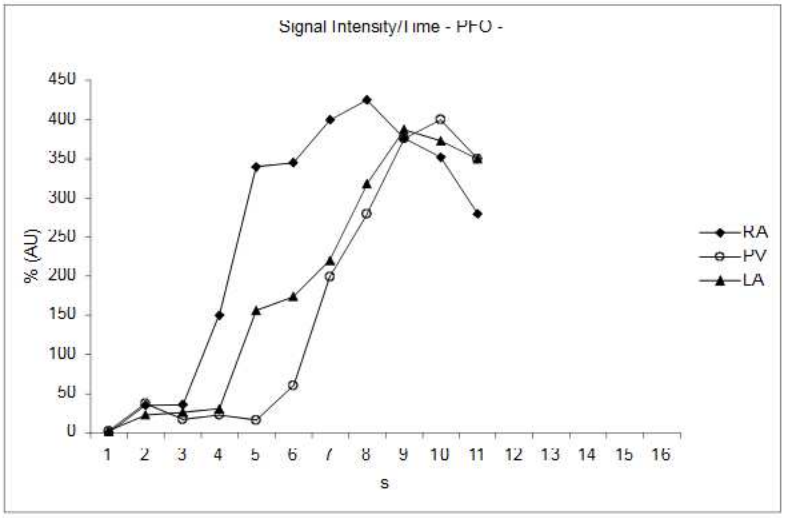

Graphs plotting signal-intensity (percent of baseline value) of the blood-pool over time (seconds after contrast administration) in a patient with intact IAS (**a**) and a patient with PFO (**b**). Note the premature increase in signal-intensity in LA in a patient with PFO. **RA** indicating right atrium; **PV**, pulmonary veins; **LA**, left atrium

At 6 months after PFO closure MRPI revealed sufficient defect closure in patients without residual transseptal shunt on TEE. However MRPI missed correct diagnosis in 1 out of 2 patients showing minimal provoked residual right-to-left transseptal shunt after PFO closure. No false positive findings were stated by MRPI neither in patients with PFO nor in patients with ASD.

In patients with ASD a spontaneous transseptal wash-out of contrast agent out of RA due to a left to right shunt was inconstantly observable in the paraseptal region. During VM premature arrival of contrast agent in LA due to transseptal shunting could be demonstrated in all patients with ASD. However MRPI missed correct diagnosis in 1 out of 2 patients showing minimal residual left-to-right transseptal shunt after ASD closure. Figure xy shows the IAS after percutaneous defect closure

Figure XY: ECG-gated GRE in 4-chamber view orientation in a patient after percutaneous ASD-closure. Note the signal-void caused by artefacts due to metallic components of the device. Right- and left-atrial sides of the umbrella-device can clearly be discerned (arrows).

Discussion: Aim of our study was to assess the diagnostic performance of MRI in the evluation of transseptal shunts in patients with PFO and ASD before and after percutaneous defect-closure. We could demonstrate that a dedicated contrast-enhanced MRI-protocol with provoked right-to-left shunt yields good diagnostic performance in the primordial diagnosis of IC and, with reservations, also during follow-up after percutaneous IC-closure. Our preinterventional findings are in good accordance to the work of Mohrs et al.[23] who chose a similar MRI-protocol for patients with PFO only.

In recent years various approaches how to estimate ASD-size and transatrial shunt-volume by MRI have been proposed. The morphological defect is well identifiable with standard MRI-procedures such as anatomical imaging with Spin-echoes (SE) and cine-imaging with Gradient-echoes. Holmvang et al. reported that ASD-size is overestimated with SE-techniques and may lead to false-positive results because of focal signal void due to septal thinning in the fossa ovalis. Good correlation of defect-area to surgical findings was achieved by through-plane transatrial phase-contrast imaging (PCI) in a slice-orientation parallel to the IAS[24]. Our experience with SE in this study is in good accordance to the work of Holmvang et al.. Phase-contrast-measurement of blood-flow in the ascending aorta and pulmonary

artery is an established method to non-invasively determine shunt-volume via estimation of Qp/Qs-ratio but was not performed in our study since quantification of left-to-right shunt was not the pivotal question addressed.

Up to the present PFO has not been diagnosable by standard MRI-techniques since the temporal and spatial resolution of SE as well as cineGE and even steady-state-free-precession (SSFP) does not allow for detection of the short-time separation of septum primum and secundum during atrial systole and under provoked right-to-left shunt. For PFO-detection neither transatrial nor Qp/Qs PCI-techniques can be applied since a significant shunt-quantum is lacking. To our knowledge the first successful attempt to visualize PFO by MRI by means of a contrast-enhanced perfusion-sequence was recently reported[23]. However, there are no data available addressing visualization of residual shunts with MRI after percutaneous IC-closure. According to studies on safety of MRI in patients with cardiovascular implants, the used closure device is not affected by MRI six months after implantation < Prasad SK, Pennell DJ. Safety of cardiovascular magnetic resonance in patients with cardiovascular implants and devices. Heart. 2004 Nov;90(11):1241-4. Shellock FG. Magnetic resonance safety update 2002: implants and devices. J Magn Reson Imaging. 2002 Nov;16(5):485-96. Review.>.

After defect-closure all commonly available MRI-approaches to evaluate IC and transatrial shunt are limited. Neither SE nor cineGE imaging are dependable due to artefacts caused by the occluder-device in the IAS-region. According to our own experience image-quality is even more reduced in SSFP sequences than in standard GE due to higher liability for artefacts caused by the occluder-devices. Estimation of Qp/Qs ratio by PCI only makes sense for large shunts which are unlikely to persist after percutaneous IC-closure. Furthermore, through-plane PCI in an imaging-plane orientation parallel to the IAS cannot be applied since the residual transatrial shunt is only minute and is mechanically dispersed by the occluder.

However, our approach demonstrates that the limitations of current standard MRI techniques in the diagnosis of minimal transatrial shunts in patients with PFO and during follow-up after percutaneous closure of both IC-types can in parts be overcome by non-invasive dynamic contrast-enhanced MRI with provoked right-to-left shunt. This method shows good sensitivity and excellent specificity in the initial diagnosis of IC. After percutaneous defect closure the diagnostic specificity remains high but diagnostic sensitivity decreases. We believe that this is due to the fact that the marginal transatrial shunt is even further reduced and dispersed mechanically by the occluder device. Additionally, the

temporal resolution of the MRPI-sequence is limited and this feature is crucial when visualization of short time, small quantum transatrial shunts is addressed. Visual assessment of transatrial right-to-left shunt under provocation can be assisted by computational analysis of signal-time curves in paraseptal LA, RA and the pulmonary veins and help establishing correct diagnosis.

Limitations: Limitations of the present study are the small number of patients and the relatively low incidence of residual shunts after percutaneous defect closure. Thus, the transferability of our findings into a routine setting is limited. Further studies with larger patient populations, especially with residual shunts after percutaneous defect closure, are needed to confirm these initial results.

Additionally, for successful appliance of the described method it is mandatory that patients execute the Valsalva maneuver correctly. This might be hampered by neurological deficits such as aphasia in patients with paradoxical cerebral embolism or in patients who require sedation during MRI due to claustrophobia. On the ground that blood-flow from the inferior vena cava is targeted directly towards the IAS via the Eustachian valve it has been proposed to perform contrast-injection via the femoral vein[22]. However, this method is obsolete in clinical routine so that we set aside this approach for our study. Last but not least, up to now MRI is still more expensive and less disposable than echocardiography. This might be overcome in future when cardiovascular MRI is more widely established in cardiology.

Summary: Defects of the IAS can be reliably visualised by cineGE in patients with ASD and by MRPI in patients with PFO. Despite local artefacts due the implanted devices sufficient defect closure can be documented. In summary MRI might prove as a valuable alternative in patients who decline frequent TEE during follow-up after percutaneous defect-closure or in patients with contraindications for TEE.

LITERATURE

1. Hagen PT, Scholz DG, Edwards WD. Incidence and size of patent foramen ovale during the first 10 decades of life: an autopsy study of 965 normal hearts. Mayo Clin Proc. Jan 1984;59 (1):17-20.
2. Meyer RA, Korfhagen JC, Covitz W, et al. Long-term follow-up study after closure of secundum atrial septal defect in children: an echocardiographic study. Am J Cardiol. Jul 1982;50(1):143-148.

3. Moss AJ AF. Heart disease in infants, children and adolescents including the fetus and the young. 5 ed. Baltimore: Williams and Wilkins; 1995.

4. Lechat P, Mas JL, Lascault G, et al. Prevalence of patent foramen ovale in patients with stroke. N Engl J Med. May 5 1988;318(18):1148-1152.

5. Stone DA, Godard J, Corretti MC, et al. Patent foramen ovale: association between the degree of shunt by contrast transesophageal echocardiography and the risk of future ischemic neurologic events. Am Heart J. Jan 1996;131(1):158-161.

6. Graham TP, Jr. Ventricular performance in congenital heart disease. Circulation. Dec 1991;84 (6):2259-2274.

7. Bogousslavsky J, Garazi S, Jeanrenaud X, et al. Stroke recurrence in patients with patent foramen ovale: the Lausanne Study. Lausanne Stroke with Paradoxal Embolism Study Group. Neurology. May 1996;46(5):1301-1305.

8. Campbell M. Natural history of atrial septal defect. Br Heart J. Dec 1970;32(6):820-826.

9. Ezekowitz MD, Bridgers SL, James KE, et al. Warfarin in the prevention of stroke associated with nonrheumatic atrial fibrillation. Veterans Affairs Stroke Prevention in Nonrheumatic Atrial Fibrillation Investigators. N Engl J Med. Nov 12 1992;327(20):1406-1412.

10. Homma S, Sacco RL, Di Tullio MR, et al. Effect of medical treatment in stroke patients with patent foramen ovale: patent foramen ovale in Cryptogenic Stroke Study. Circulation. Jul 4 2002;105(22):2625-2631.

11. Homma S, Di Tullio MR, Sacco RL, et al. Surgical closure of patent foramen ovale in cryptogenic stroke patients. Stroke. Dec 1997;28(12):2376-2381.

12. Windecker S, Wahl A, Nedeltchev K, et al. Comparison of medical treatment with percutaneous closure of patent foramen ovale in patients with cryptogenic stroke. J Am Coll Cardiol. Aug 18 2004;44(4):750-758.

13. Braun M, Gliech V, Boscheri A, et al. Transcatheter closure of patent foramen ovale (PFO) in patients with paradoxical embolism. Periprocedural safety and mid-term follow-up results of three different device occluder systems. Eur Heart J. Mar 2004;25(5):424-430.

14. Braun MU, Fassbender D, Schoen SP, et al. Transcatheter closure of patent foramen ovale in patients with cerebral ischemia. J Am Coll Cardiol. Jun 19 2002;39(12):2019-2025.

15. Messe SR, Silverman IE, Kizer JR, et al. Practice parameter: recurrent stroke with patent foramen ovale and atrial septal aneurysm: report of the Quality Standards Subcommittee of the

American Academy of Neurology. Neurology. Apr 13 2004;62(7):1042-1050.

16. Wu LA, Malouf JF, Dearani JA, et al. Patent foramen ovale in cryptogenic stroke: current understanding and management options. Arch Intern Med. May 10 2004;164(9):950-956.

17. Brochu MC, Baril JF, Dore A, et al. Improvement in exercise capacity in asymptomatic and mildly symptomatic adults after atrial septal defect percutaneous closure. Circulation. Oct 1 2002;106(14):1821-1826.

18. Attie F, Rosas M, Granados N, et al. Surgical treatment for secundum atrial septal defects in patients >40 years old. A randomized clinical trial. J Am Coll Cardiol. ˇ%\ù h 2001;38(7): 2035-2042.

19. Belkin RN, Pollack BD, Ruggiero ML, et al. Comparison of transesophageal and transthoracic echocardiography with contrast and color flow Doppler in the detection of patent foramen ovale. Am Heart J. Sep 1994;128(3):520-525.

20. Chee TS, Quek SS, Ding ZP, et al. Clinical utility, safety, acceptability and complications of transoesophageal echocardiography (TEE) in 901 patients. Singapore Med J. Oct 1995;36(5): 479-483.

21. Rebergen SA, de Roos A. Congenital heart disease. Evaluation of anatomy and function by MRI. Herz. Jun 2000;25(4):365-383.

22. Hamann GF, Schatzer-Klotz D, Frohlig G, et al. Femoral injection of echo contrast medium may increase the sensitivity of testing for a patent foramen ovale. Neurology. Jun 1998;50(5): 1423-1428.

23. Mohrs OK, Petersen SE, Erkapic D, et al. Diagnosis of patent foramen ovale using contrast-enhanced dynamic MRI: a pilot study. AJR Am J Roentgenol. Jan 2005;184(1):234-240.

24. Holmvang G, Palacios IF, Vlahakes GJ, et al. Imaging and sizing of atrial septal defects by magnetic resonance. Circulation. ˇ%\ù h 15 1995;92(12):3473-3480.